



PATIENT

Hinata Clingenpeel

SPECIES

Feline

BREED

DSH

SEX

Female

AGE

8 months

WEIGHT

5.5lbs

INTERPRETED BY

Maggie Machen Lamy,
DVM, DACVIM
(Cardiology)

IMAGING PERFORMED BY

Annette Anleu, DVM

HOSPITAL NAME

Ellwood Animal
Hospital

REFERRING VET

Dr. Jones

INVOICE

47598

DATE

4/16/26

PRESENTING CLINICAL SIGNS

History: Grade 2/6 heart murmur. ECG showed LAD.

-Abnormal PE/Chem/CBC/UA Results: Neutrophils 2.464 – low, Phosphorus 6.7 - high, Cholesterol 79 – low, BNP normal at 24.

ECHOCARDIOGRAM FINDINGS

2D, m-mode, color flow and doppler imaging is available. The left ventricular wall is normal in dimension. The papillary muscles are normal in size. The endocardium appears normal. The left atrium is normal in size. The right atrium is normal in size. The right ventricle appears normal. The mitral valve is normal in structure and mobility. No MR. Normal flow through both the RVOT and LVOT. No TR. No AI or PI. No pleural or pericardial effusion seen. No congenital shunts are visualized.

CARDIAC CHART

FELINE CARDIAC PARAMETERS	BODY WEIGHT (kg)	HR (BPM)	IVSd (cm) <small>(Moise, Pipers)</small>	LVIDd (cm) <small>(Moise, Pipers)</small>	LVWd (cm) <small>(Moise, Pipers)</small>	FS (%)	EF (%)
NORMAL PARAMETER	-----	150-240	0.35-0.55	<2 (mean 1.5)	3.5-0.55	35-67	80-100
PATIENT	2.5	230	0.39	1.0	0.39	50	85
FELINE CARDIAC PARAMETERS	LA/AO <small>(Boon)</small>	LA/AO HEART BASE (Swe) <small>(Abbott)</small>	LA 2D short axis Base view (cm) <small>(Abbott)</small>	LVOT VEL (m/s)	RVOT VEL (m/s)	E max (m/s)	
NORMAL	<1.5	<1.3	<1.2	<1.6	<1.3	<0.9	
PATIENT	NM	1.3	0.9	1.2	1.3	NM	

**Note: All measurements based upon multi-modal images and methods. An average value is reported.*
Adapted from June Boon, Veterinary Echocardiography, 1998
Abbott J & MacLean H JVIM 2006;20: 111-119, Moise et al. Am J Vet Res 47:1476, 1986. Pipers et al. Am J Vet Res 40:882, 1979.

INTERPRETATION OF THE FINDINGS & FURTHER RECOMMENDATIONS

Overtly normal cardiac structure and function. The LV wall thickness is normal and there is no evidence of elevated left atrial pressure. No obvious congenital issues are documented. No cause for the murmur is clearly identified. That being said, if the murmur persists without a diagnosis, referral to a local Cardiologist is always recommended as small abnormalities are easily missed in congenital cases.

Given these findings, no medications are indicated. It is important to note that phenotypic HCM can develop at any phase of life in cats and often does not accompany a heart murmur or PE abnormalities. Periodic screening is ideally recommended in all cats.

No cardiac contraindication for general anesthesia at this time.

Recommend recheck echocardiogram in 1 year.



PATIENT

Hinata Clingenpeel

SPECIES

Feline

BREED

DSH

SEX

Female

AGE

8 months

WEIGHT

5.5lbs

INTERPRETED BY

Maggie Machen Lamy,
DVM, DACVIM
(Cardiology)

IMAGING PERFORMED BY

Annette Anleu, DVM

HOSPITAL NAME

Ellwood Animal
Hospital

REFERRING VET

Dr. Jones

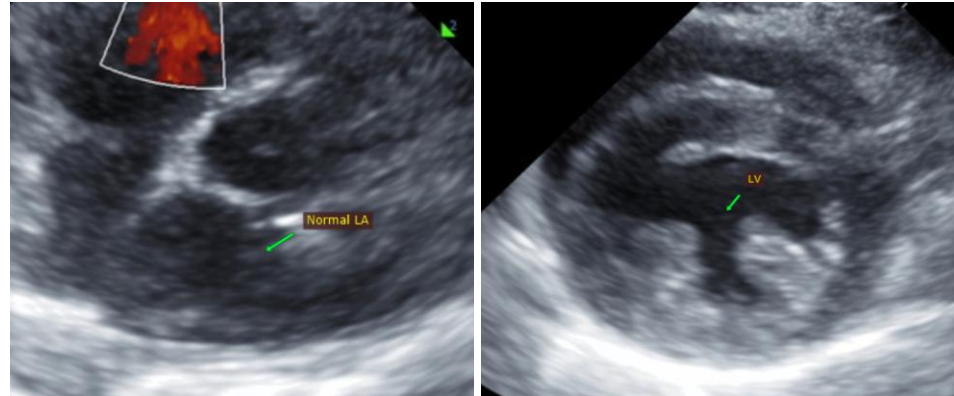
INVOICE

47598

DATE

4/16/26

IMAGES



The information and recommendations provided are based on the images presented by the referring veterinarian. No evaluation can be communicated regarding pathology that was not visible in the image/video clips provided.

Thank you for this referral. This report was generated using transcription software, and minor dictation errors may be present. If the clinical or image interpretation does not parallel your findings or if I can be of any further assistance, please contact me.

Maggie Machen Lamy, DVM
Diplomate of the American College of Veterinary Internal Medicine (Cardiology)
info@sonopath.com